
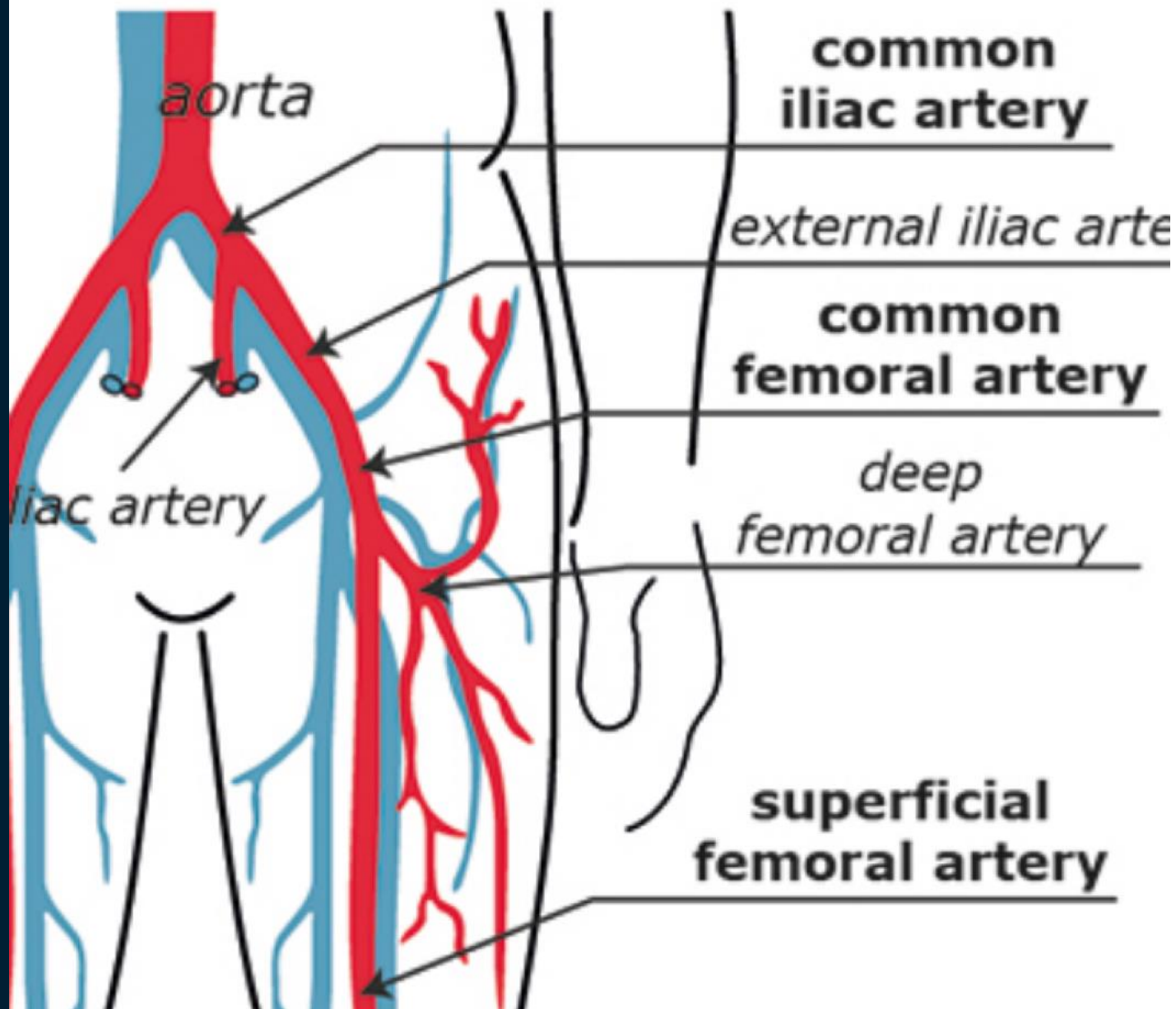


Traitement endovasculaire des lésions du trépid femoral

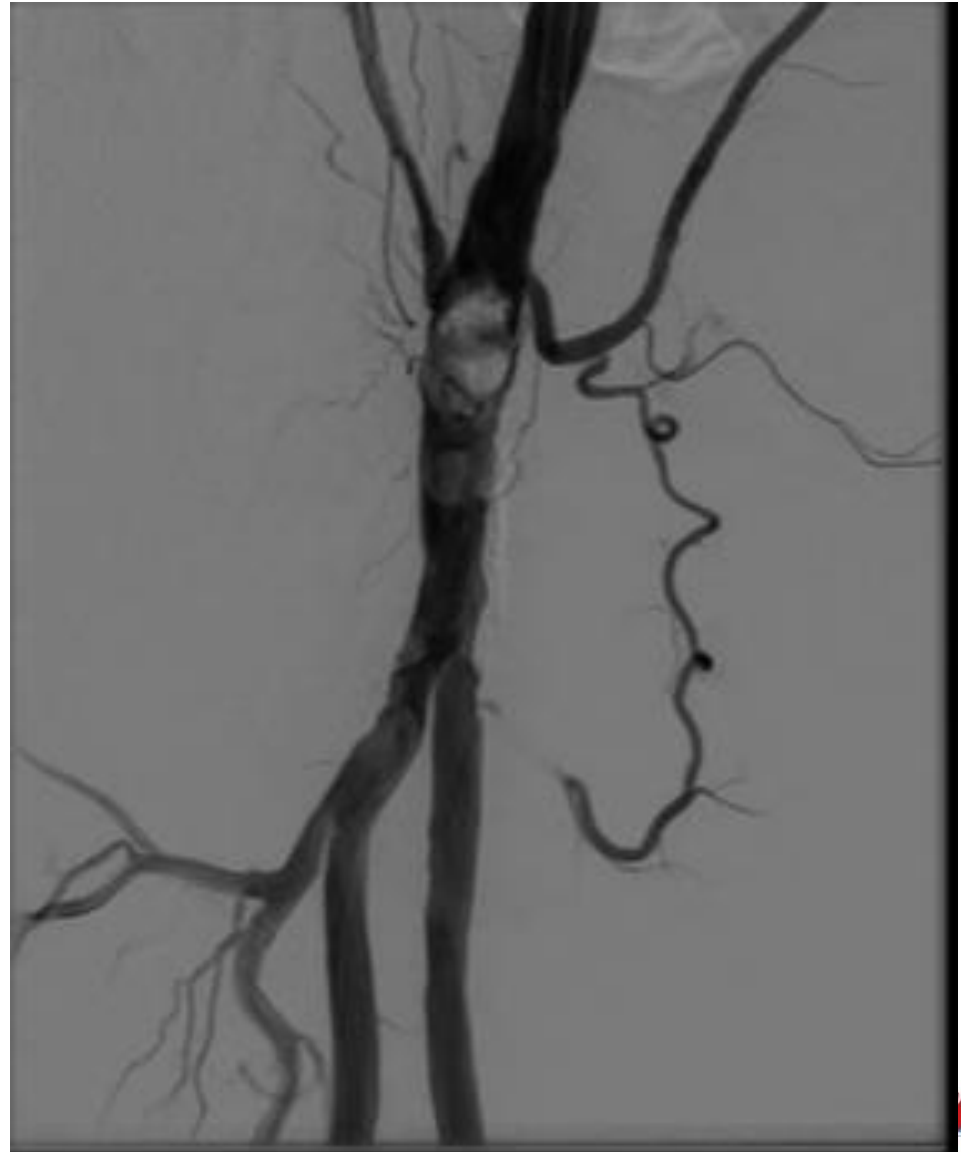
Alexandra HAUGUEL, Interne DESC 3^e année Chirurgie Vasculaire
Department of vascular surgery, University hospital of Nantes, France

l'institut du thorax





Lésions distales de l'AFC

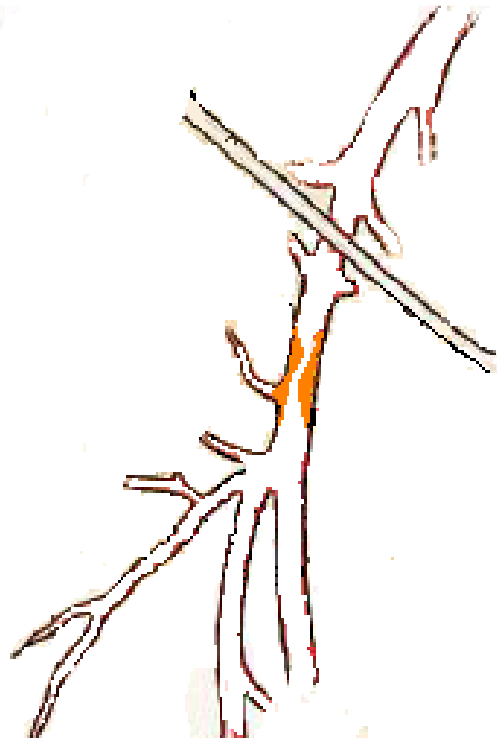


Lésions ostiales de AFS/AFP

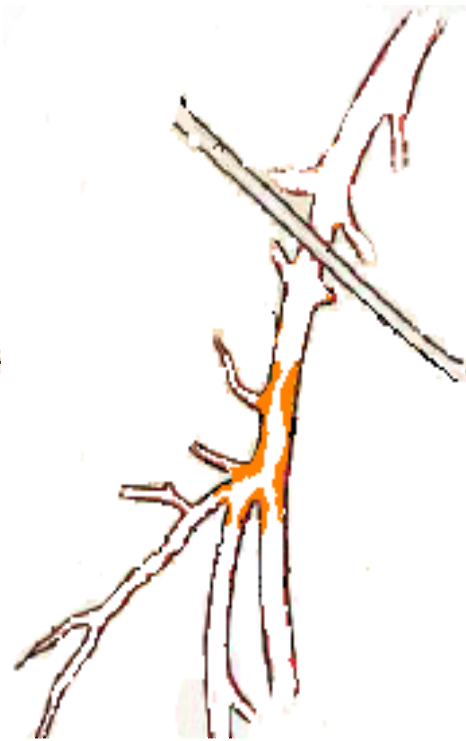Type 1



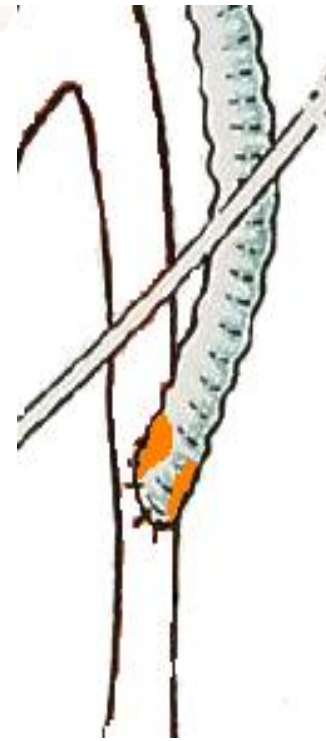
Type 2



Type 3



Type 4



Traitement

Gold standard

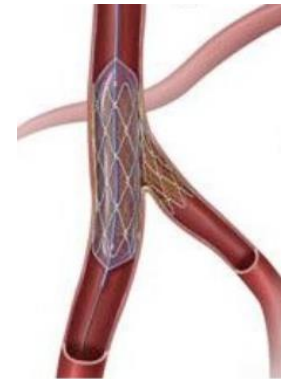
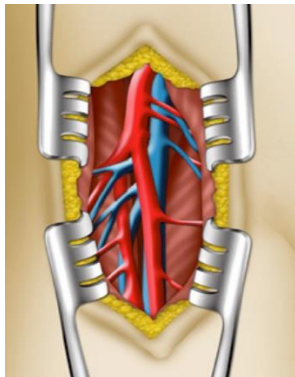
Médical

Chirurgical

Chirurgie ouverte

Hybride

Endovasculaire



Stenting de l'AFC, pourquoi pas?

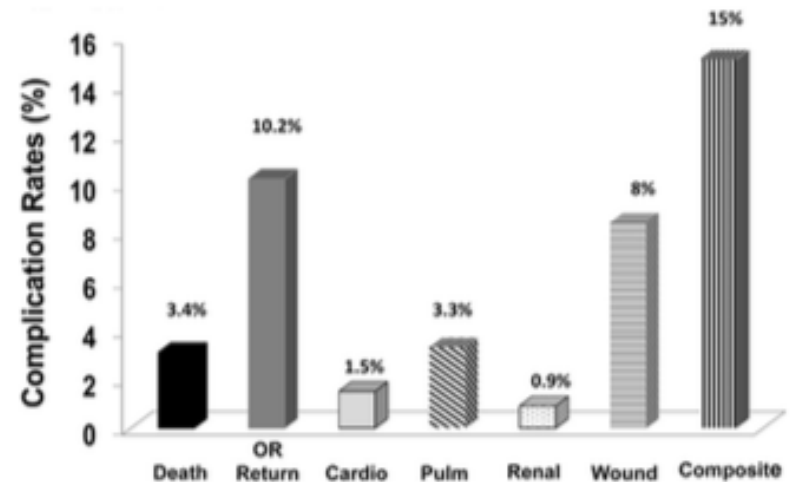
- Scarpa=zone de mobilité ++?
- Durabilité, fracture stents?
 - Calcifications?
 - Chirurgie « facile »?
- Compromission de futures voies
d'abord?



Postoperative complications after common femoral endarterectomy

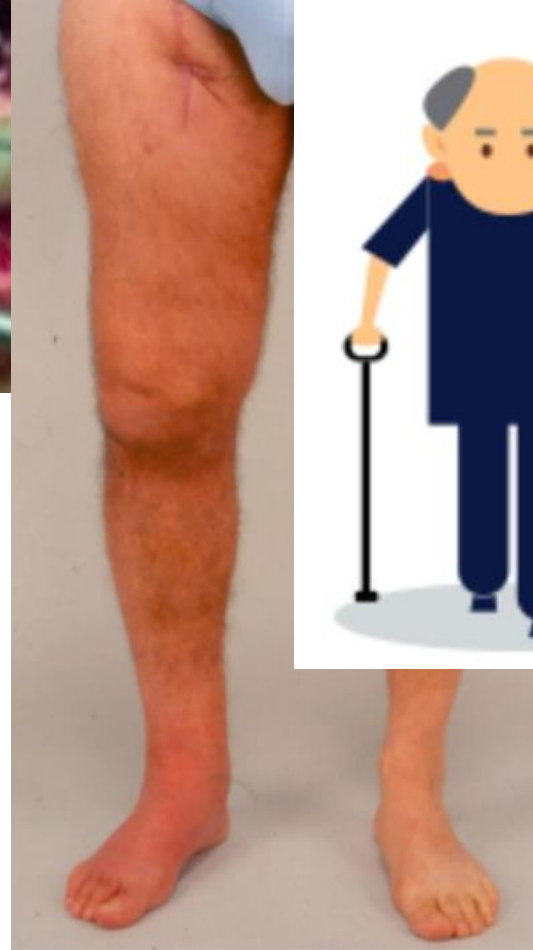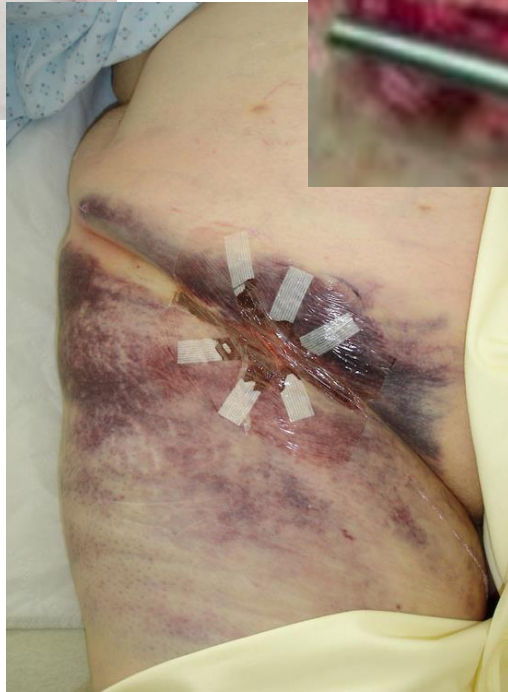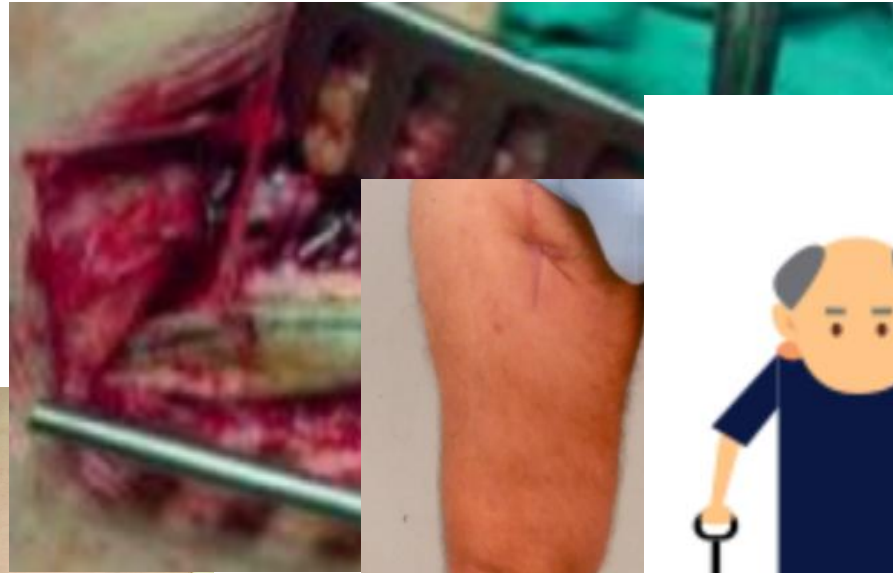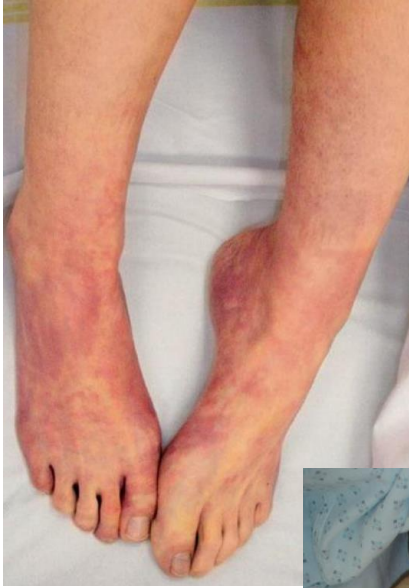Bao-Ngoc Nguyen, MD, Richard L. Amdur, PhD, Mustafa Abugideiri, BS, Rodeen Rahbar, MD, Richard F. Neville, MD, and Anton N. Sidawy, MD, MPH, *Washington, D.C.*

- 1843 CFEs, Diabetes: 33%; CLI: 36%
 - CFE between 2005-2010 from the ACS-NSQIP database
 - Perioperative morbimortality outcomes before and after hospital discharge
- Morbi-mortality rates 15%
- Average length of stay : 4.6 ± 7.5 d



Conclusions: CFE is not as “benign” a procedure as previously believed. The risks of death and wound complications are not insignificant, and a high percentage of these complications occurred after patients were discharged from the hospital. Patients should be carefully selected, especially in the elderly population, and close postoperative follow-up should be considered. (*J Vasc Surg* 2015;61:1489-94.)

Complications



Endovascular Treatment of Common Femoral Artery Disease

Medium-Term Outcomes of 360 Consecutive Procedures

Robert F. Bonvini, MD,*† Aljoscha Rastan, MD,* Sebastian Sott, MD,* Elias Noory, MD,*
Thomas Schwarz, MD,* Uleich Frank, MD,‡ Marco Roffi, MD,‡ Pierre André Doraz, PhD,‡
Uwe Schwarzwälder, MD,* Karlheinz Büchel, MD,* Roland Macharzina, MD,* Thomas Zeller, MD*
Bad Krozingen, Germany; and Geneva and Chur, Switzerland

Key findings:

- 360 limbs / CLI: 22.1%
- Lost of FU @ 10mo: 12.2%
- Perioperative complications: **6.4%**
 - Restenosis rate: 27.6%
 - TLR: 19.9%

The use of stents was identified as the only independent protective factor against procedural failure, TLR and 1-year restenosis

Bonvini, JACC, 2011



Endovascular treatment of common femoral artery obstructions

Frederic Baumann, MD,* Mirka Ruch,* Torsten Willenberg, MD,* Florian Dick, MD,* Dai-Do Do, MD,*
Hak-Hong Keo, MD,* Iris Baumgartner, MD,* and Nicolas Diehm, MD,* *Bern, Switzerland*

Key findings:

- 98 limbs / CLI: 19%
- De novo / restenosis: 85/15%
- Perioperative complications: **6.4%**
 - Bailout stenting: 27%
 - TLR: 17/46%

Primary sustained clinical improvement was significantly better in patients in whom stents had been implanted

Baumann, J Vasc Surg, 2011

Pilot study 2006-2008

40 limbs – Primary stenting

Perioperative morbi-mortality rate: 5%

clinical improvement @ 1y: 80%

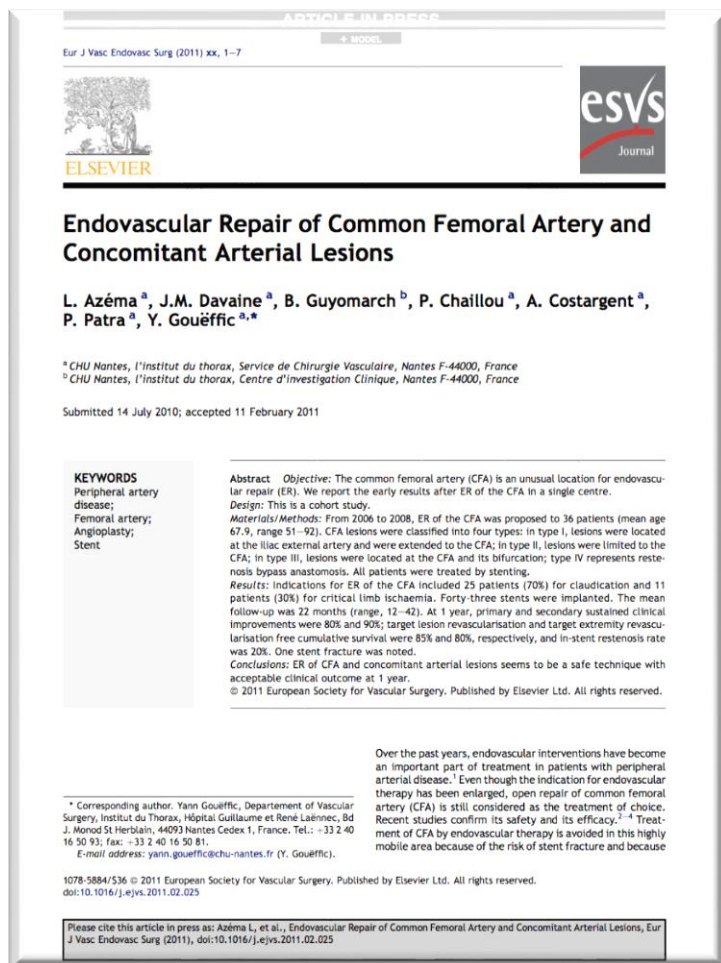
TLR free @ 1-y: 85%

In-stent restenosis rate*: 20%

Stent fracture** : 2.5%

* Defined systolic velocity peak index > 2.4

** according Jaff M., Catheter Cardiovasc Interv 2007



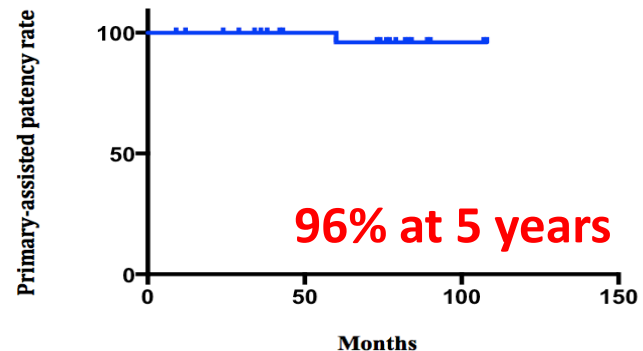
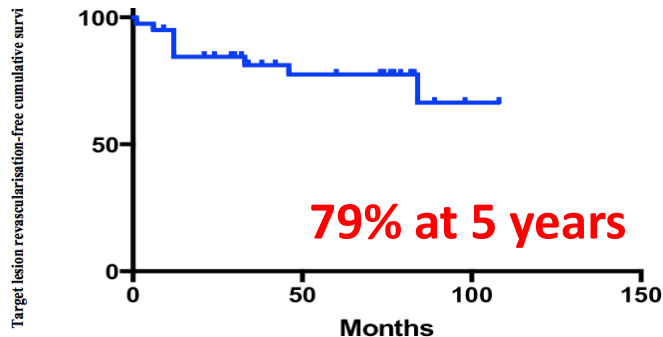
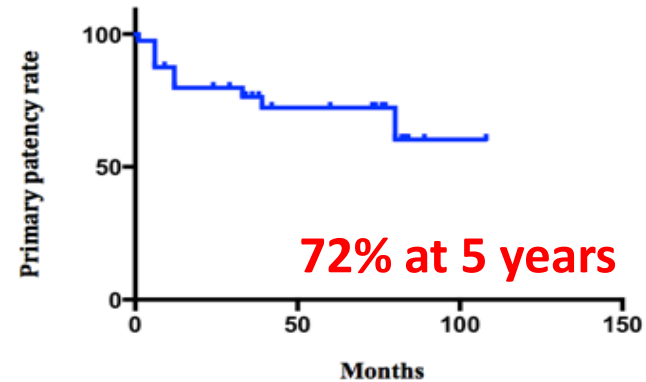
Azéma, Eur J Vasc Endovasc Surg, 2011

Long-term outcomes of common femoral artery stenting

Bahaa Nasr^a; Adrien Kaladji^b; Pierre-Alexandre Vent^c; Philippe Chaillou^c; Alain Costargent^c;

Thibault Quillard^{d,e}; Yann Gouëffic^{c,d,e}.

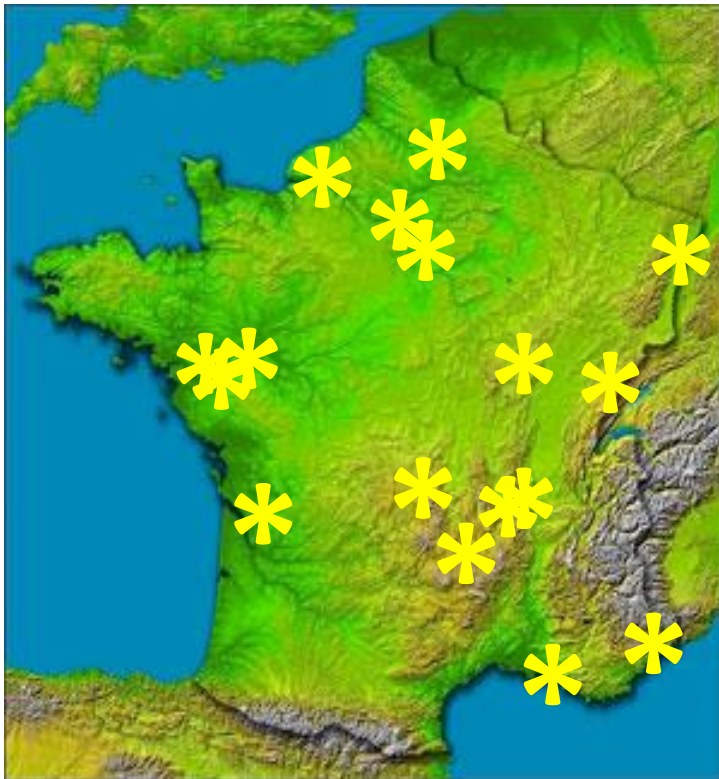
At 5 years of FU:
clinical improvement was 73%
Freedom from TLR: 79%
7 open reinterventions
4 endo reinterventions



Conclusions: Endovascular repair of the common femoral artery and its bifurcation seems to provide sustained clinical and morphological long-term results. Fear of stent fracture and local complications due to hip mobility are no longer relevant.

TECCO trial

French multicenter randomized trial comparing surgery versus stenting for the treatment of CFA atherosclerotic lesion (From 2011 to 2015)

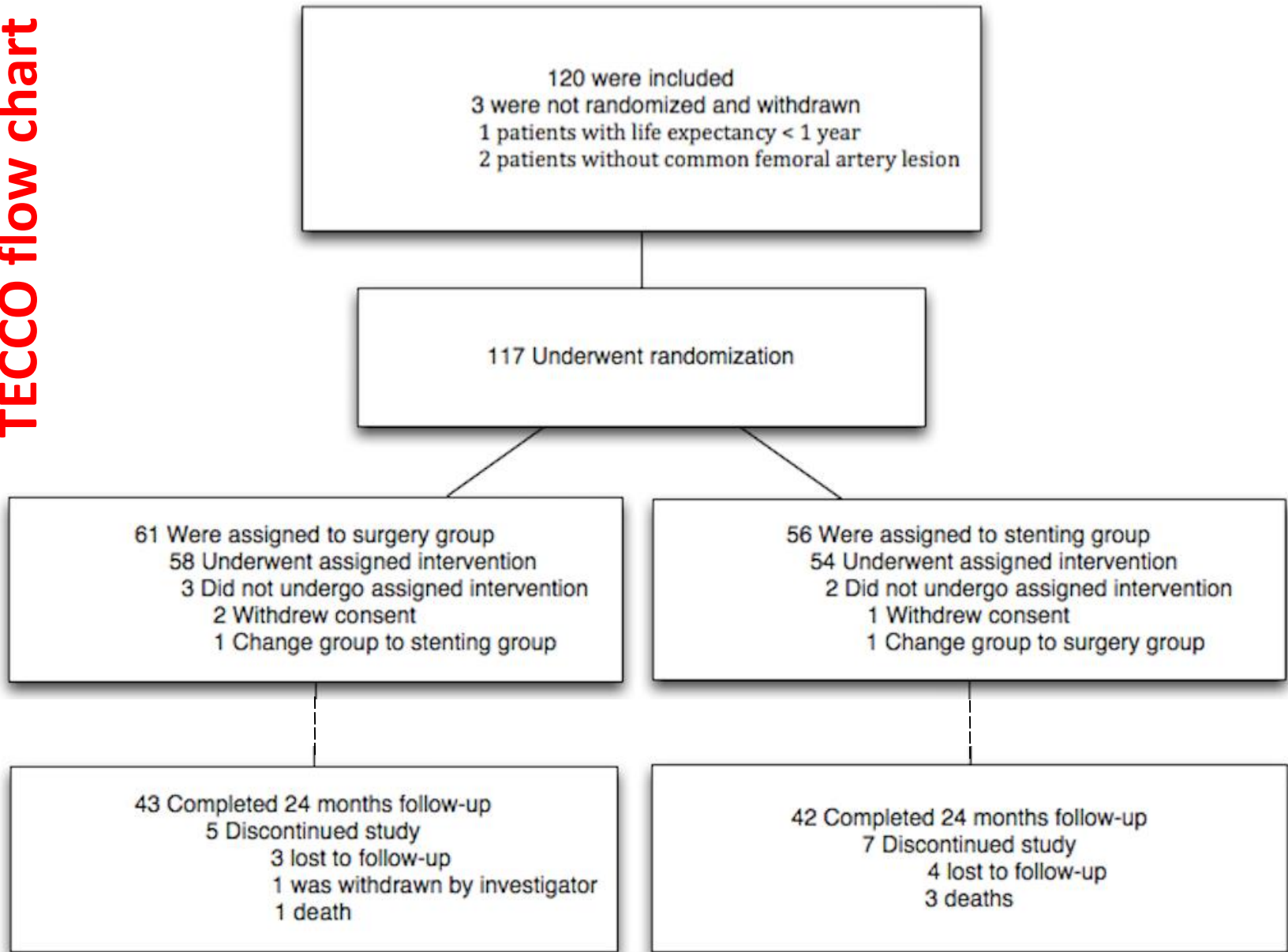


TECCO trial, NCT01353651

Sponsor Nantes University Hospital
PHRC 2010 DGOS 20-03

17 centers : CHU de Nantes (N° 1), CHU de Amiens (N° 2), CHU Besançon (N° 3), CHU de Strasbourg (N° 4), CHU de Dijon (N° 5), CHU de Clermont-Ferrand (N° 6), CHU de Nice (N° 7), CHU de Marseille (La Timone) (N° 8), CHU de Bordeaux (N° 9), CHU de Lyon (N° 10), CHU de St Etienne (N° 11), CHU de Rouen (N° 12), Clinique du Tonkin (N° 13), Nouvelles Cliniques Nantaises (N° 14), Clinique St Augustin (N° 15), HEGP (N° 16), Hopital Henri Mondor (N° 17)

TECCO flow chart



Primary endpoint

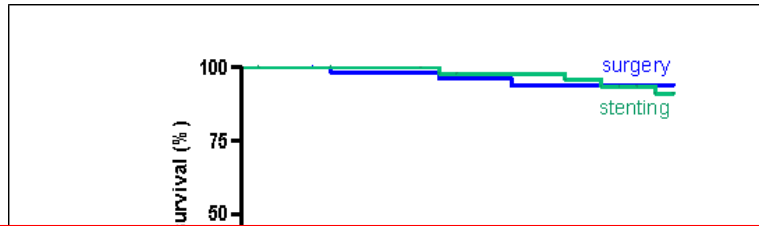
Modified intent to treat analysis

	Surgery (n=61)	Stenting (n=56)	p
Morbidity-mortality rate @ 1 month, n (%)	16 (26)	7 (12.5)	0.05

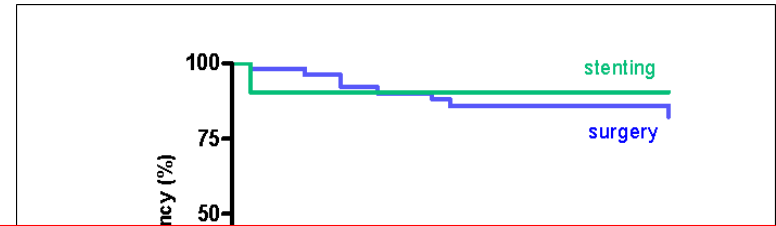
Per protocol analysis

	Surgery (n=58)	Stenting (n=47)	p
Morbidity-mortality rate @ 1 month, n (%)	16 (26)	3 (6.4)	0.005

Survival @ 24 months



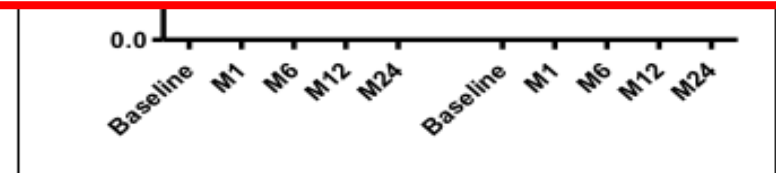
Patency @ 24 months



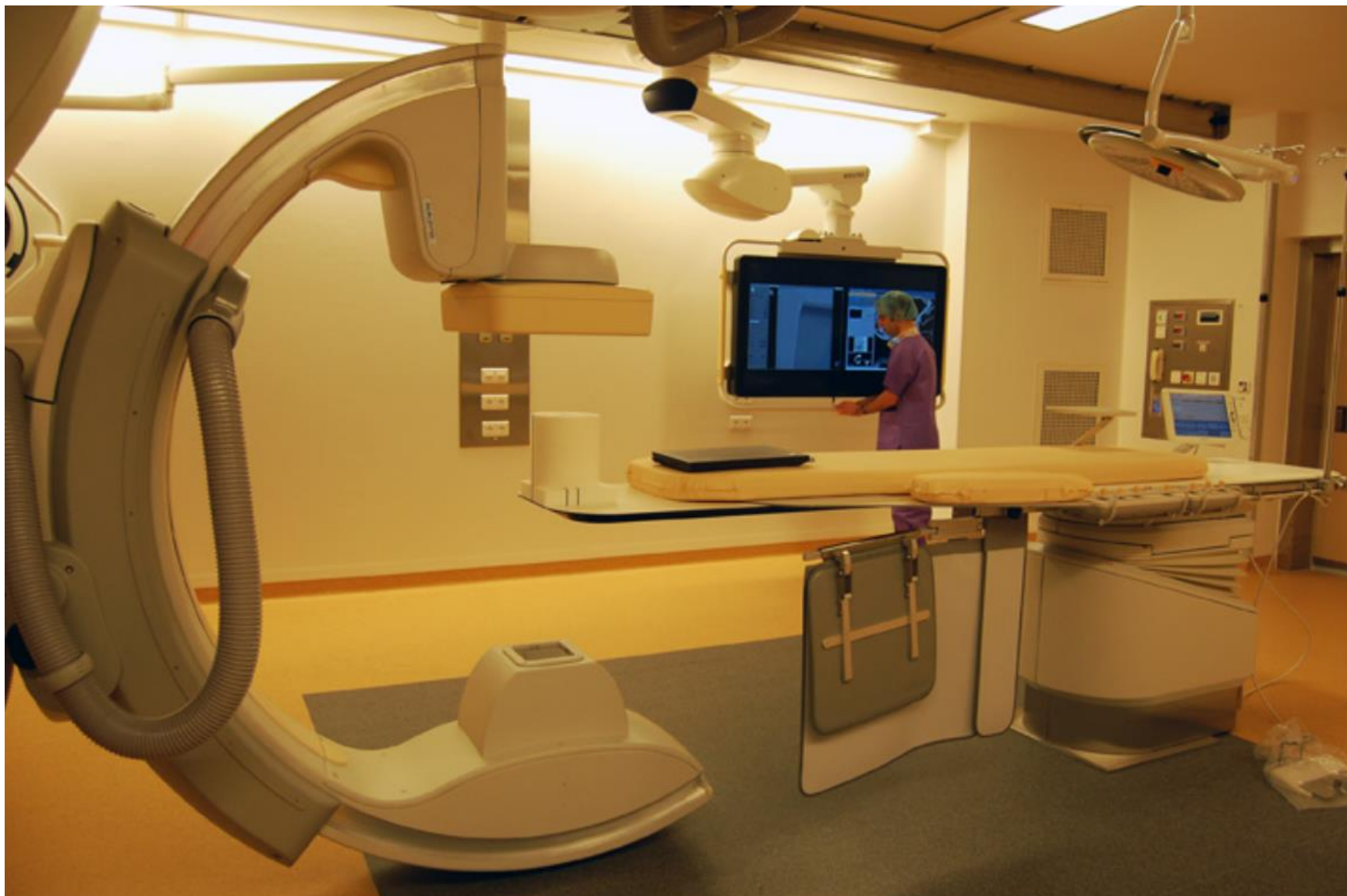TECCO take home message

The results of the TECCO trial support a significant benefit of stenting over surgery with respect to the perioperative morbidity and mortality rate among patients with de novo atherosclerotic stenosis of the CFA.


	Time(months)				
No. at Risk					
Surgery	59	51	47	40	28
Stenting	55	48	46	42	27



Procédure



Matériel?



Matériel en salle

ABORD

Aiguilles de ponction
Intro long 6F / 45cm




CROSSOVER

Guide stiff Terumo 260
Sonde UF



RECANALISATION

Guides Stiff 032/ Souples 014
Ballon standard
Sonde de reca



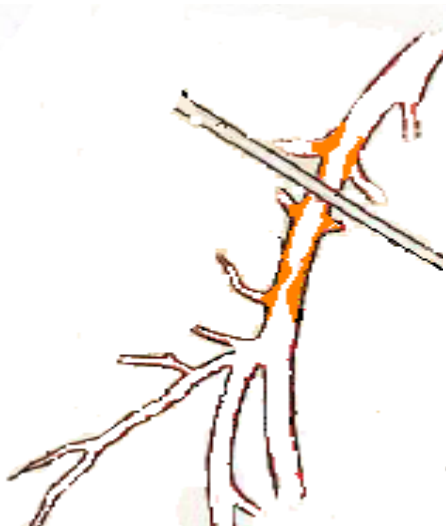STENTING

Nitinol autoexp
Acier Balloon exp

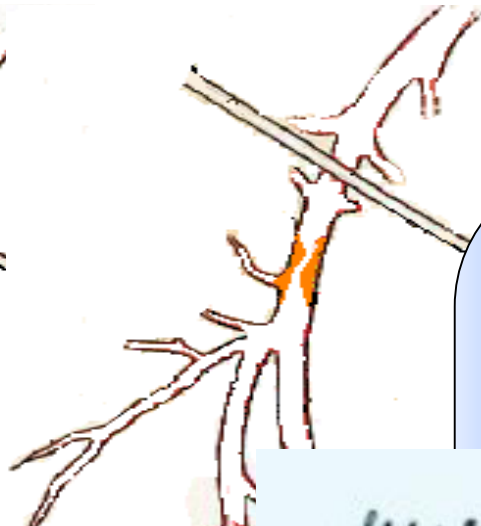Quel stent ?

Plaques très calcifiées – « Crush risk » – Préserver future voie d'abord

Type 1




Type 2



AFC

**NITINOL, Grande force radiaire
Auto-expansible**



Quel stent ?

Type 3

Type 4





AFP/AFS

Aciers

Balloon-expandable

Précision de largage ++





Take Home Message



- Chirurgie du trépied fémoral: pas si dénué de risque
- Recanalisation endovasculaire du trépied fémoral: bon résultats à long terme, moins de complications

Take Home Message



- Matériel adapté au type de lésions: lésions courtes calcifiées/Stents à grande force radiaire
- Equipes entraînées